

Protective role of Ethanolic Leaf Extract of *Annona Squamosa* (L.) on Experimentally Induced Hepatocellular Carcinoma

Vanitha Varadharaj^{1*}, Uma Devi Kumba Janarathanan²,
Vijayalakshmi Krishnamurthy³

¹Department of Biochemistry, School of Lifesciences, Vels University,
Pallavaram, Chennai – 600117. Tamilnadu. India.

²Department of Biochemistry, Bhaktavatsalam Memorial College for Women,
Korattur, Chennai-600 080. Tamilnadu. India.

³Department of Biochemistry, Bharathi Women's College,
Chennai – 600 108. Tamilnadu. India.

Abstract: *Annona squamosa* Linn, commonly known as Sugar apple, belonging to the family Annonaceae, is said to show varied medicinal effects, including insecticide, antiovolatory and abortifacient. The present work was intended to investigate the effect of ethanolic leaf extract of *Annona squamosa* on den induced hepatocellular carcinoma in wistar albino rats. The study was carried out to analyze the biochemical parameters like Total Proteins, Bilirubin, Enzymatic and Non –Enzymatic enzymes, Marker enzymes and Tumor markers in serum and also the histopathological studies in liver is carried out in control and DEN induced rats. Supplementation of ELAS (Ethanolic Leaf Extract of *Annona squamosa*) reduces the liver weight and the tumor incidence. Chemoprevention group showed near normal values of bilirubin when compared with the control rats. Total protein was decreased in the cancer bearing group and on treatment with the extract the levels of protein were restored. Both in pre and post treatment group, the activities of enzymatic antioxidants such as superoxide dismutase, catalase, and GPx were increased but in pre treated animals it was more effective than post treated animals. The non- enzymatic antioxidants such as vitamin C and vitamin E were brought back to normal level significantly in post and pre treated animals. Activities of marker enzymes such as SGOT, SGPT, ALP, γ GT were significantly elevated in the serum of cancer animals and the values returned to normal after treatment with the extract suggesting the hepatoprotective effect of the extract. Lipid peroxide was found to be elevated in the cancer induced group. This condition was brought back to the normal in the pre and post treated animals with ELAS. Histological examination also confirmed the anti-carcinogenic potential of ELAS, Cancer induced groups had a triple fold increase in their AFP values when compared to other groups. DEN treatment increased the level of AFP expression while ELAS partially counteracted the effect of it. So the scientific validation obtained from this study may be recommended for the hepatoprotective treatment using the leaves of *Annona squamosa* as effective herbal remedies.

Key words: *Annona squamosa*, Cancer, Chemoprevention, Hepatoprotective, Tumor.

Introduction

Cancer is widely recognized as one of the most formidable human afflictions. It exists in more than 100 forms and has many causes, from genetic factors to infections. Liver cancer is one of the most common malignancies worldwide, especially in Asia and Africa. Hepatocellular Carcinoma (HCC) is one of the most

common malignancies in the world. (1). HCC accounts for about 80% - 90% of all liver cancer and is the fourth most common cause of cancer mortality (2). Due to the global pandemic of hepatitis B and C viral infections, the incidence of HCC is rapidly increasing in Asian and Western countries (3-4). The prognosis of advanced HCC remains poor and novel treatment and diagnosis strategies are urgently needed. Major risk factors for liver cancer include hepatitis viral infection, food additives, alcohol, aflatoxins, environmental and industrial toxic chemicals, and air and water pollutants (5).

In experimental anticancer studies, attempts are made to identify agents which could exhibit the following characteristics such as prevention of tumor initiations, delay or arrest in the development of tumors and reduction in cancer metastasis. The major focus of the research in recent days includes development of new and safe cancer chemopreventive agents from natural source.

Liver plays an important role in the metabolism and disposition of a large number of foreign chemicals. Experimental hepatocarcinogenesis can be induced by various chemical carcinogens such as diethylnitrosamine (DEN), Aflatoxin B1 etc. Diethylnitrosamine (DEN) is a well known potent hepatocarcinogenic agent present in tobacco smoke, water, cured and fried meals, cheddar cheese, agricultural chemicals, cosmetics and pharmaceutical products (6-8). DEN is known to induce damage to many enzymes involved in DNA repair and is normally used to induce liver cancer in experimental animal models.

A large number of agents including natural and synthetic compounds have been identified as having some potential cancer chemopreventive value. Plants and plant products have been shown to play an important role in the management of various liver disorders. The new and recent approach of chemoprevention serves as an attractive alternative to control malignancy (9). An alternative and novel approach for the management of HCC is chemoprevention through the recommended intake of health protective food especially those present in vegetables, fruits, beverages and spices in daily diet which inhibits or reverses the development of cancer. Plants and plant products have been shown to play an important role in the management of various liver disorders. Therefore, search for safe and more effective agents has continued to be an important area of active research. Since ancient times, diabetes has been treated orally with several medicinal plants or their extracts based on folklore medicine.

Annona squamosa L. (Annonaceae), known as custard apple, is a small, semi-(or late) deciduous, much branched shrub or small tree, commonly found in deciduous forests and also cultivated in wild in various parts of India. It is a native of West Indies, now cultivated throughout India and other tropical countries. Literatures of many research works prove that every parts of *Annona squamosa* possess medicinal property. Roots are employed internally in depression of spirits and spinal diseases. Bark is known to be a powerful astringent. In Ayurveda, the traditional system of Indian medicine, its fruits are considered as a good tonic, enrich blood, used as expectorant, increases muscular strength, cooling, lessens burning sensation and tendency to biliousness, sedative to heart and relieves vomiting (10). Due to uniqueness of leaf property in curing of different ailments, the present investigation was undertaken to evaluate the protective role of ethanolic leaf extract of *Annona squamosa* (ELAS) on DEN induced HCC in wistar albino rats.

Materials and Methods

Chemicals

DEN was purchased from Sigma Chemical Co., USA. All other reagents and chemicals used in the study were of analytical reagent grade and of highest quality available, and were purchased from reliable firms and institutes (SRL, MERCK, RANBAXY, HIMEDIA, SIGMA and SUYOG). Standard kits for LPO, SOD and CAT were obtained from Cayman Chemicals, USA.

Preparation of Plant Material

Fresh leaves of *Annona squamosa* plant was collected locally during the month of November to January. The taxonomic identification of these plant materials was authenticated by Prof. P. Jayaraman, Director, Plant Anatomy Research Centre, Chennai, India. (PARC / 2009 /456). The leaves were shade dried and was macerated with 100 mL of ethanol and stored for 72 hrs in ice cold condition. After 72 hrs the extracts were filtered through a Whatmann filter paper No. 42 (125 mm) and the organic layer was allowed to evaporate. The resulted dark green extracts were concentrated using a rotary evaporator with a water bath set at 40° C. The concentrated crude extracts were lyophilized into paste (5 and 15 g respectively) and were taken for the investigation.

Selection of Animal and Ethics

Male albino rats of Wistar strain, weighing about 150 – 200 g were obtained from BRULAC, Saveetha University; Chennai- 77 and used for the experiments. Animals were kept in animal house at an ambient temperature of 25 °C and 45 – 55% relative humidity, with 12 h each of dark and light cycles. Animals were fed pellet diet and water *ad-libitum*. Experimental animals were handled according to the University and Institutional Legislation, regulated by the committee for the purpose of Control and Supervision of Experiments on Animals (CPCSEA), Ministry of Social Justice and Empowerment, Government of India. (IAEC No.Biochem BWC.007/2009).

Induction of Experimental Animal

Diethylnitrosamine(DEN) was administered at a standard dose of 200mg/kg body weight, as an intraperitoneal injection (11). The ethanolic leaf extract of *Annona squamosa* (ELAS) was given 350 mg/kg body weight in rats (12) Silymarin (2.5 mg/kg BW) was used as a standard drug (13). Rats were divided into five groups as follows.

Experimental Setup

- GROUP I : Normal rats (n=7, the animals were given normal saline only)
- GROUP II : Hepatocarcinoma induced rats (n=7, the animals were given DEN)
- GROUP III : Post-treated rats (n=7, the animals were given DEN+ELAS)
- GROUP IV : Pre- treated rats (n=7, the animals were given ELAS+DEN)
- GROUP V : Drug control rats (n=7, the animals were given DEN+Silymarin).

Treatment Protocol

Group I Control animals received normal saline only. In Group II, III and IV animals liver cancer was induced with DEN by a single intraperitoneally injection (200 mg/kg body weight). After two weeks carcinogenic effect was promoted in all the groups by Phenobarbital (0.05%, PB). Promoter was supplemented to the animals through drinking water up to 14 successive weeks (14). At the beginning of 15th week Groups III animals received ELAS (350/kg body weight/day) (12) dissolved in saline and fed orally for 30 consecutive days. Group IV animals received ELAS for 30 days and then liver cancer was induced with DEN induced followed by Phenobarbital. Group V animals received Silymarin (2.5 mg/kg body weight) (13) after cancer induction and this group served as positive control.

Collection of Serum and Tissue Samples

After the experimental period the animals were sacrificed by cervical decapitation. Rats were treated as per the treatment protocol. Body weights of these rats were monitored sequentially in control and experimental animals. The blood was collected by retro orbital artery bleeding. Blood sample was centrifuged for 10 minutes at 3000 rpm to separate the serum, which was kept at -20°C until further analysis. Liver was excised immediately and kept in physiological saline. Ten-percentage homogenate was prepared with fresh tissue in 0.01 M Tris-HCl buffers (pH 7.4). Tissue homogenates were used for further analysis.

Biochemical Estimations

For biochemical investigations serum samples were utilized. All the biochemical estimations were completed within 24 hrs of animal sacrifice. Total Protein by Lowry *et al*, (15), Bilirubin by Jendrassik & Jrof (16), Superoxide Dismutase (SOD) by Marklund & Marklund (17), Catalase by Sinha (18), Glutathione peroxidase (GPx) by Rotruck *et al*, (19), Reduced glutathione (GSH) by Moron *et al*, (20), Vitamin C by Omaye *et al*, (21), Vitamin E by Desai (22), Serum Glutamate Oxaloacetate Transaminase (SGOT) by King (23) Serum Glutamate Pyruvate Transaminase (SGPT) by King (24), Alkaline Phosphatase, by King (23), Gamma Glutamate Transpeptidase (GGTP) by Orłowski & Meister, (25). The level of lipid peroxides was assayed by the method of Ohkawa *et al*, (26) in the tissue homogenate. Alpha-fetoprotein in serum was measured quantitatively by solid phase enzyme linked immunosorbent assay (ELISA) according to the method of Belanger *et al*, (27).

Histopathological Examination

Tissue specimens were fixed in 10% buffered formalin for atleast 4 hrs immediately after sacrifice. Specimens were dehydrated by passing through ascending grades of alcohol, cleared in xylene, impregnated and embedded in paraffin. These sections were cut (3-5 μ m) and were stained using haematoxylin-eosin and mounted in DPX and visualized under microscope for histological changes.

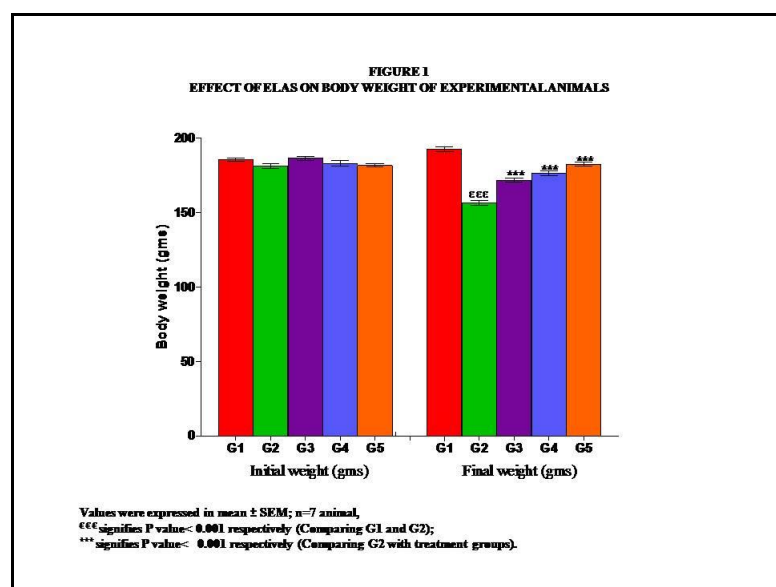
Statistical Analysis

Statistical analysis was done by using SPSS package. Values are mean \pm SD & mean \pm SEM for seven animals in each group and the significance of difference between mean values were determined by one-way analysis of variance (ANOVA).

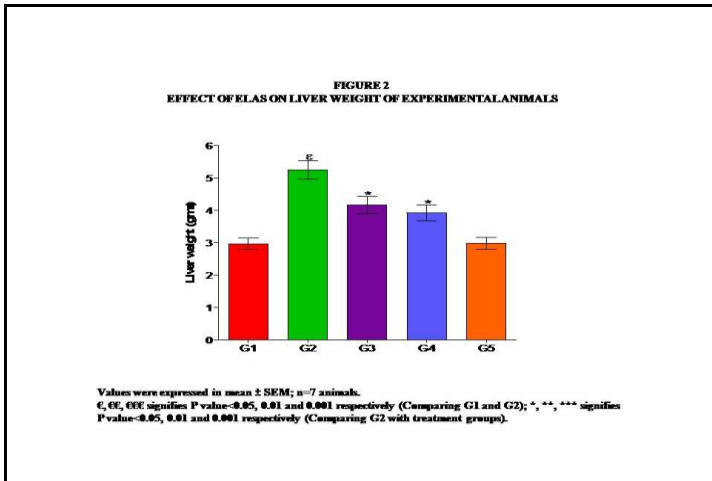
Results

All the animals treated with DEN had a significant incidence of liver tumor at the end of 14 week as evidenced by: (i) decrease in body weight (Figure 1), (ii) increase in liver weight (Figure 2), (iii) Increased Bilirubin (Figure 3), Decrease in protein (Figure 4), (iv) Decreased enzymatic antioxidants such as SOD, CAT GPx (Figure 5), (v) Decrease in non-enzymatic antioxidants such as Vitamin E, Vitamin C and GSH (Figure 6), (vi) Increased hepatic enzymes such as SGPT, SGOT, ALP and γ – GT (Figure 7), (vii) Increased AFP (Figure 8) and (viii) increased LPO (Table 1). All these biochemical changes were brought back to normal by the administration of Ethanolic leaf extract of *Annona squamosa* leaf (ELAS) indicating the strong inhibition of hepatocellular carcinoma induced by DEN.

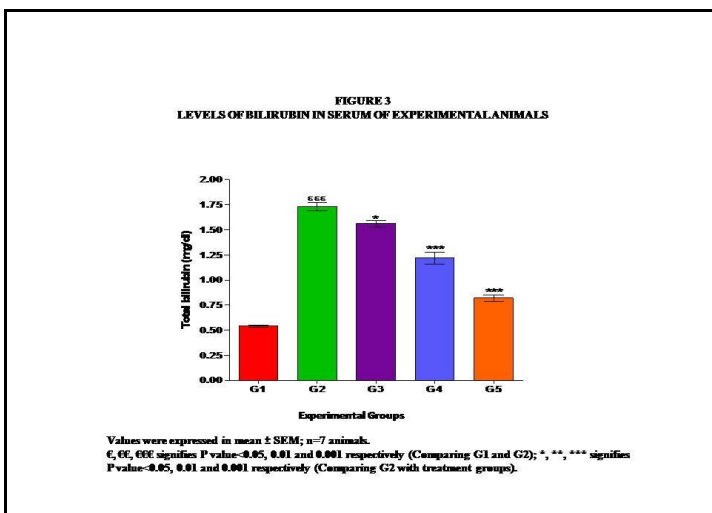
There was a significant decrease in the body weight of treated G2 animals when compared with control G1 animals (Figure 1). ELAS post treated animals G4 were found to have a significant increase in the body weight when compared with G2 animals. On pretreatment with ELAS, G4 animals showed a significant increase in the body weight when compared G2 animals. In silymarin treated rats G5 the final body weight was found to be increased significantly when compared with G2 animals.



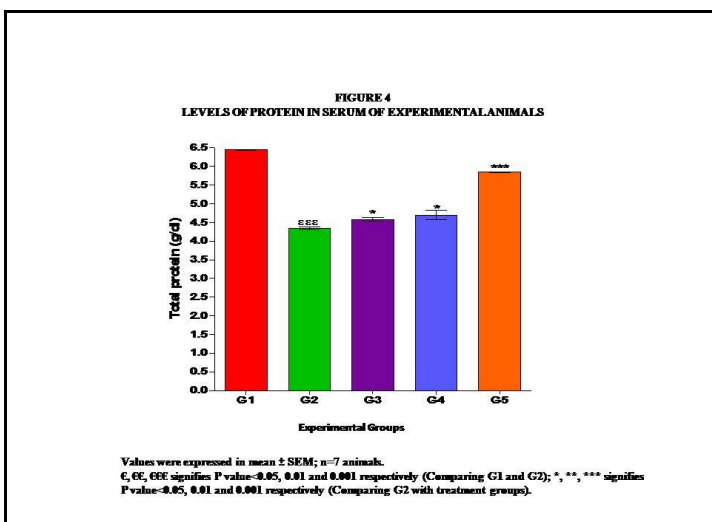
There was a significant increase in liver weight of G2 animals when compared to G1 control rats. However ELAS supplementation also reduced liver weight in G3 and G4 animals when compared with G2 animals (Figure 2). G3 and G4 animals treated with ELAS showed a significant decrease in cancer incidence when compared with cancer bearing animals.



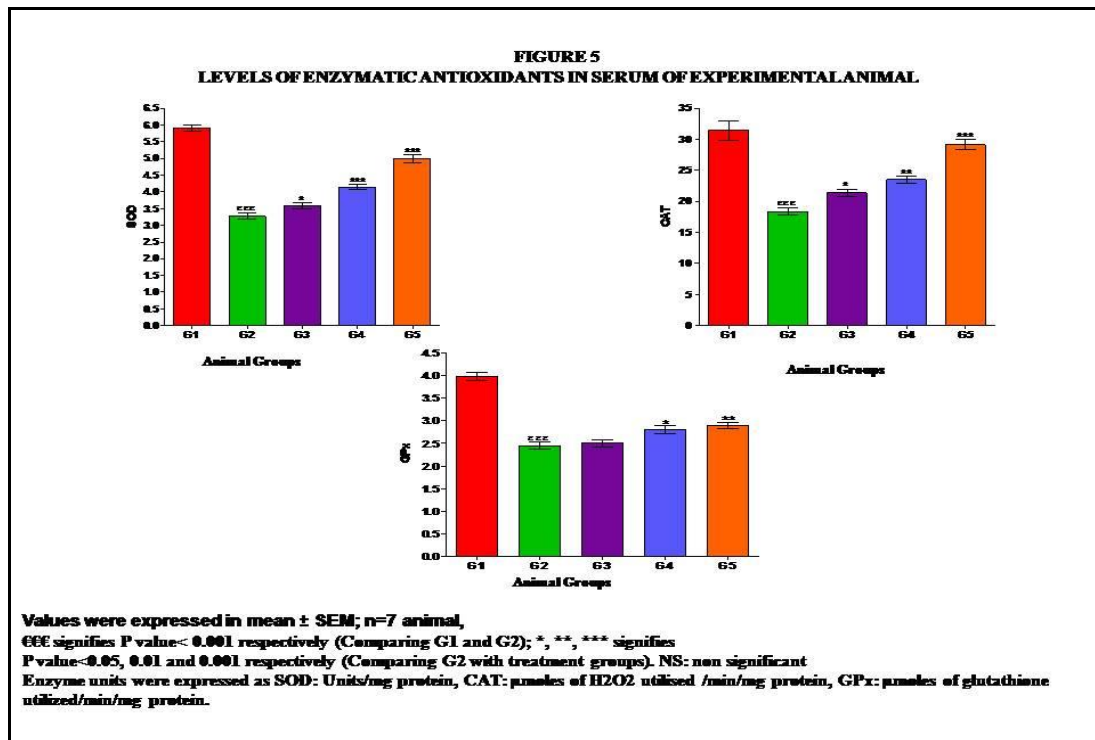
There was a significant increase in total bilirubin in DEN induced rats G2 when compared to normal G1 and it is decreased in post treated group G3 when compared to G2 but it still remains higher when compared to G1. There was significant decrease in bilirubin in pre treated group G4 when compared to G2 but it is to near normal when compared to G1 (Figure 3). There was significant decrease in bilirubin in drug control group G5 when compared to G3 but it is to near normal when compared to G1.



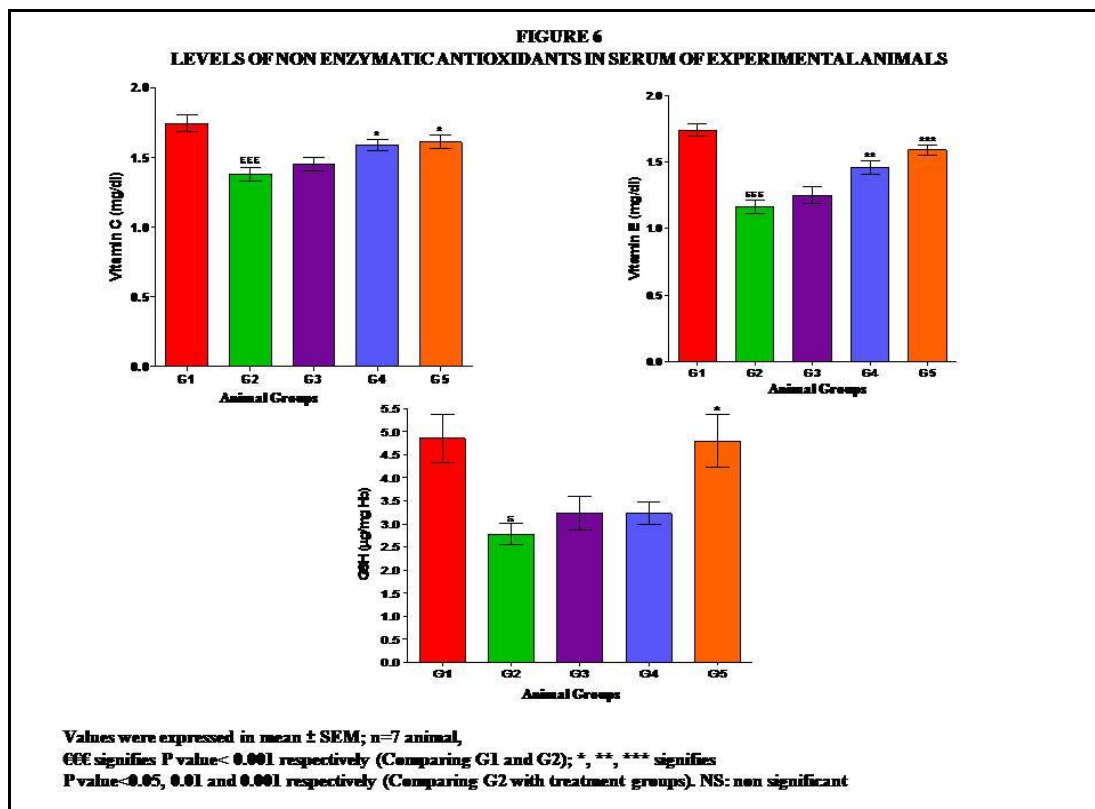
There was a significant decrease in total protein in DEN induced rats G2 when compared to Normal G1. The level of total protein in post treated group was found to be increased when compared to G2 but it still remains lower when compared to G1 (Figure 4). The levels of total protein in pretreated and drug control groups were found to be nearly same and it is decreased when compared to G2 and G1.



The enzymatic antioxidants such as Superoxide dismutase, Catalase, and Glutathione peroxidase were significantly ($P < 0.001$) reduced in G2 animals when compared with G1 animals (Figure 5). Both post and pre treated (G3 and G4) animals, the levels were increased but in G4 it was more effective than G3. In G5 the levels were significantly ($P < 0.001$) increased when compared to G2.



The non-enzymatic antioxidants such as vitamin C, vitamin E and GSH were significantly reduced in G2 animals when compared with G1 animals. Both post and pre treated (G3 and G4) animals, these changes were brought back to near normal (Figure 6).



The levels of SGOT, SGPT, ALP and γ -GT are increased in serum of DEN induced rats G2 and it is found to be decrease in post treated group G3, pretreated G4 and Drug control groups when compared to G2. The activities of SGOT, SGPT, ALP and γ -GT in G5 are found to be higher when compared to G1 (Figure 7).

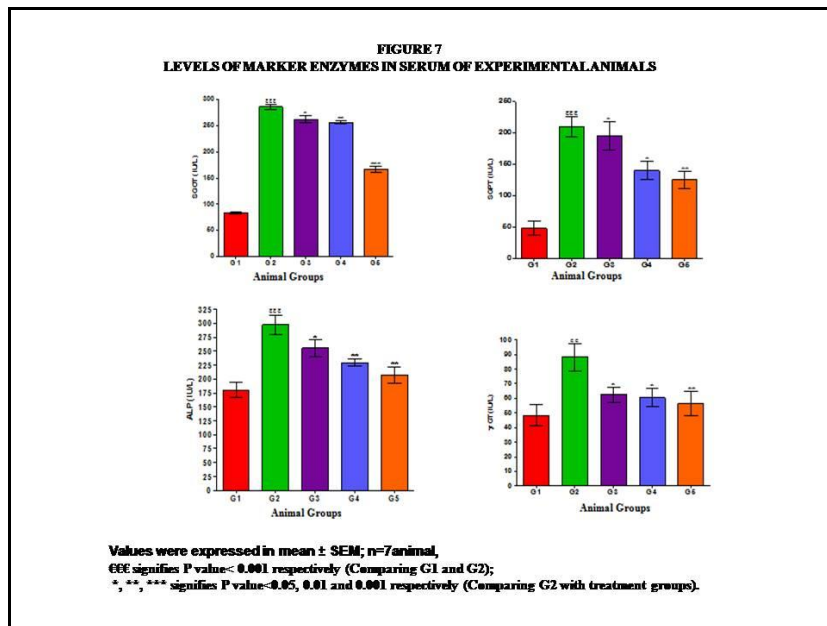
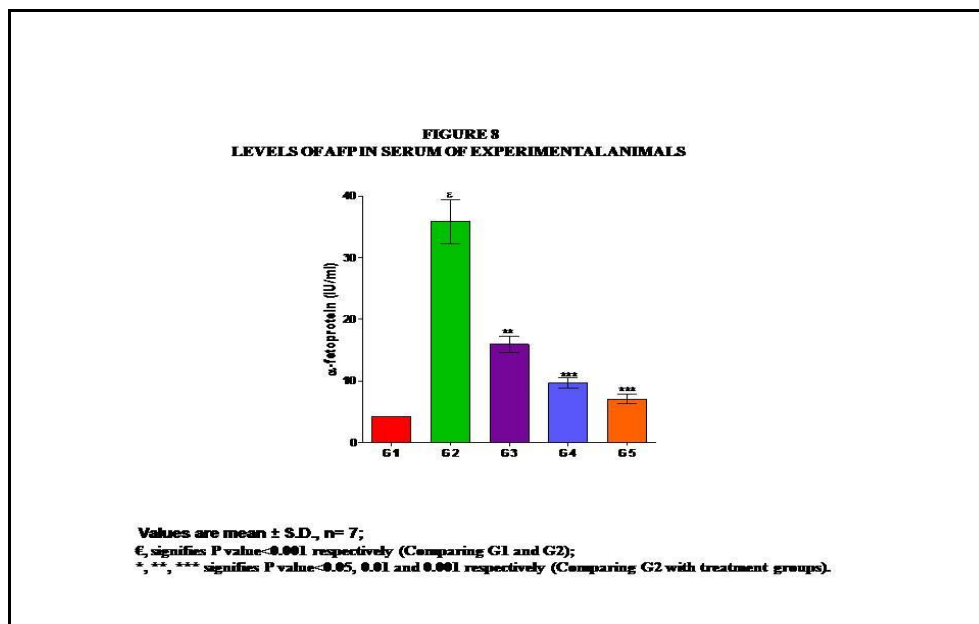


Figure 8 portrays the serum AFP concentration in normal control rats and the experimental groups. The result of the AFP levels exhibited comparable changes ($p < 0.001$) after experimental manipulation. 10 IU/ml is the upper limit of normal AFP value in rats. G2 animals had a triple fold increase in their AFP values when compared to the other groups. G3, G4 & G5 showed near normal values. DEN treatment augmented the level of alpha-fetoprotein while ELAS partially counteracted the effect of it. The level of AFP attributes a significant cyto-protective effect on the hepatocytes and the exact mechanisms through which the cyto-protective effect is exerted remains to be defined.



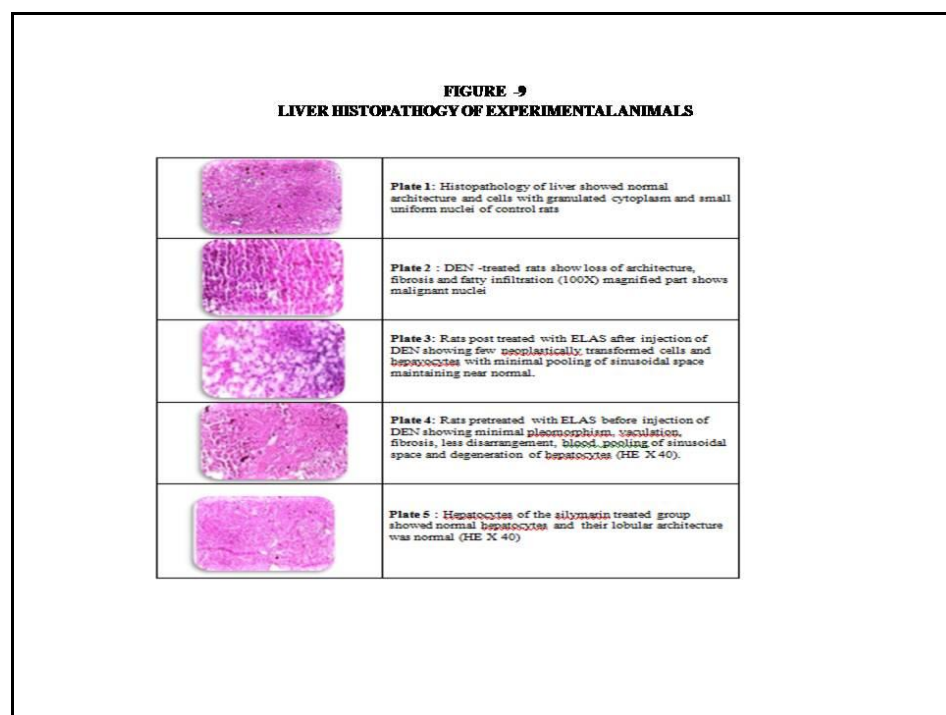
From Table 1 it was observed that there was a significant increase in the levels of LPO in induced rats G2 when compared with Normal rats G1. The increased levels of LPO was reduced significantly in post and pre treated groups (G3 and G4) when compared with G2 animals. The level of LPO in G5 was near normal when compared to G1 and also low when compared to G3 and G4.

Table 1: Levels of Lipidperoxides in Liver Tissue of Experimental Animals

S.No	Animal groups	Lipid peroxide nm/mg protein)
1.	G1	2.82±0.27
2.	G2	4.53±0.39 [€]
3.	G3	3.26±0.21 ^{NS}
4.	G4	2.99±0.12*
5.	G5	2.90±0.54*

Values were expressed in mean ±SEM; n=7 animals.
[€], signifies P value<0.05 respectively (Comparing G1 and G2);
^{*}, ^{**}, ^{***} signifies P value<0.05, 0.01 and 0.001 respectively (Comparing G2 with treatment groups).

Figure 9 shows the histopathological examination of liver sections from control group 1 animals showed normal architecture and cells with granulated cytoplasm and small uniform nuclei of control rats (Plate 1). Group 2 animals revealed loss of architecture, fibrosis and fatty infiltration part showed malignant nuclei. (Plate2). In Group 3 animals post treated with ELAS after injection of showed few neoplastically transformed cells and hepacyocytes with minimal pooling of sinusoidal space maintaining near normal (Plate 3). Whereas group 4 animals pretreated with ELAS showed minimal pleomorphism, vaculation, fibrosis, less disarrangement, blood pooling of sinusoidal space and degeneration of hepatocytes (Plate 4). Group 5 animals post treated with silymarin showed normal hepatocytes and their normal lobular architecture (Plate 5).



Discussion

The preliminary phytochemical studies have revealed the presence of alkaloids, tannins, phytosterols and flavonoids. The present study described herein indicates that the administration of ELAS has chemo preventive effects against induced HCC in Wistar albino rats. The ELAS produced significant reductions in the liver tumor incidence and tumor multiplicity and significant increase in body weight. In liver cancer bearing (G2) animals, there was a sharp decrease in their body weight. It was hypothesized that the metabolic alterations found in tumor-bearing rats may resemble a stressful situation common to other pathological conditions. This may be due to the cancer cachexia. Cancer cachexia occurs most frequently in tumor and is associated with more than 20% of cancer deaths. During cancer, progressive reduction of skeletal muscle mass occurs, although visceral protein reserves are preserved and the liver mass may actually increases (28). On drug

treatment (G3 and G4), the gradual increase in body weight indicates the antineoplastic property of the drug. G5 animals do not show any significant variation. In liver cancer bearing animals the significant tumour progression may be due to the enormous proliferation of the cancer cells. On drug treatment the significant tumor regression may be due to the inhibitory action of the drug on tumor growth. This indicates the positive nature of ELAS as a potential anticancer agent.

The elevated level of bilirubin was observed in the group II, DEN induced rats in this present study corresponded to the extensive liver damage induced by toxin. The reduced level of bilirubin as a result of ELAS administration observed during the present study might probably due to the presence of flavonoids in ELAS. The plasma proteins level may be decreased in some liver diseases and its dysfunction.

In this study the results suggest that the statistically significant difference in biochemical parameters in G2, indicate that hepatic damage has been induced by DEN. Following treatment with ELAS and Silymarin the bilirubin and total protein level was restored to normal value.

In the present investigation, DEN induced hepatocellular damage is clearly evidenced by the marked decrease in the activity of serum SOD, CAT and GPx. SOD and CAT constitute a team of mutually supportive antioxidative enzymes, which provide protective defense against reactive oxygen species. The endogenous antioxidant system may counteract the ROS and reduce the oxidative stress with the enzymatic antioxidants SOD, CAT and GPx. The decline in the activities of these enzymes in the present study could be attributed to the excessive utilization of these enzymes in inactivating the free radicals generated during the metabolism of DEN. The restoration in the activities of these enzymes after ELAS administration for 30 days indicates that ELAS acts as an effective antioxidant. ELAS possess phytochemicals like flavanoids, alkaloids and tannins, which have been shown to be effective in scavenging free radicals (29). This indicates the antioxidant potency of the ELAS by the following mechanism. Generation of reactive oxygen species can activate protein kinases including Protein Kinase C (PKC) (30). Induction of PKC leads to the induction of some proto-oncogenes such as c-fos and c-jun (31). As an antioxidant the active component present in ELAS may inhibit PKC activity by competing with ATP binding site (32). The ELAS itself may scavenge free radicals and/ or prevent the antioxidants from ROS and additionally the ELAS can act by up regulating endogeneous antioxidant defenses. Therefore by acting as an alternate radical scavenger, ELAS can replenish these antioxidant enzymes, thereby preventing oxidative stress.

The decreased levels of these antioxidant vitamins and GSH observed during DEN administration might be due to the excessive utilization of these vitamins in scavenging the free radicals formed during the metabolism of diethylnitrosamine. ELAS treatment effectively restored the depleted levels of these non-enzymatic antioxidants caused by diethylnitrosamine. ELAS has been reported to maintain the GSH homeostasis in the system and this might be the reason for elevated glutathione levels observed during silymarin treatment. Increase in GSH levels in turn contributes to the recycling of other antioxidants such as vitamin-E and vitamin-C (33). This shows that ELAS maintains the levels of antioxidant vitamins by maintaining GSH homeostasis, thereby protecting the cells from further oxidative stress.

Serum SGOT, SGPT and ALP are the most sensitive markers employed in the diagnosis of hepatic damage because these are cytoplasmic in location and are released into the circulation after cellular damage (34). Several studies have reported similar elevation in the activities of SGOT and SGPT during DEN administration (35). Treatment with ELAS for 30 days significantly reduced the levels of these marker enzymes in DEN treated rats. This indicates that ELAS tends to prevent liver damage by maintaining the integrity of the plasma membrane, thereby suppressing the leakage of enzymes through membranes, exhibiting hepatoprotective activity. This might be the reason for the restoration in the activities of the marker enzymes during administration of ELAS.

Administration of ELAS in DEN induced animals the level of LPO should decrease; lipid peroxidation can be prevented at the initiation stage by free radical scavengers and antioxidants (36) defense system of cells. From the preliminary study it is clear that ELAS contains relatively abundant flavonoid which may inhibits the level of LPO and significantly increases the enzymatic and non enzymatic antioxidant defense mechanisms in DEN experimental hepatocellular carcinogenesis. Furthermore the study underlines the capacity of the Phytochemicals in ELAS to inhibit the LPO production and modulate the antioxidants, in addition proving that the effect on a given enzyme system may be dependent on the structure.

Further, histopathological studies showed a significant reduction of mitotic level and hyperplasia in the livers of animals treated with ELAS and DEN those treated with DEN alone.

All these observations clearly indicate the hepatoprotective role of ELAS on DEN induced hepatocellular carcinoma. Preliminary phytochemical studies have shown the presence of alkaloids and flavonoids in ELAS. Flavonoids are known to possess antimutagenic and antimalignant effects. Moreover, flavonoids have a chemopreventive role in cancer through the induction of enzymes affecting carcinogen metabolism and inhibit various activities of tumor promoters, which are involved in the process of carcinogenesis.

Conclusion

It may be inferred from the present study that the hepatoprotective activities of the Ethanolic leaf extract of *Annona squamosa* (ELAS) in DEN-induced hepatocarcinoma may involve its antioxidant or oxidative free radical scavenging activities by alleviating lipid peroxidation through scavenging of free radicals, or by enhancing the activity of antioxidants (SOD and CAT). The mechanism of action is yet to be investigated but may be due to the antioxidant effects of saponins, flavonoids and free radical scavenging properties found to be present in the leaves. This plant has immense potential and have broad spectrum of activity on several ailments. The global changing scenario is showing a tendency towards use of nontoxic plant products having good traditional medicinal background. This plant can be used safely for longer duration as a cheap source of active therapeutics for alleviation of commonly occurring ailments by the poor and under privileged people of India. Also, the results from this study have confirmed the rationale for the folkloric use of the ELAS in the treatment of cancer related hepatic disorders.

References

1. Hubert EB (2003). Molecular therapy and prevention of HCC. <http://www.hccl.html/> accessed May 2003.
2. Harris CC, Sun T (1984) Multifactoral etiology of human liver cancer. *Carcinogenesis* 5:697–701.
3. Keiichi F, Yuji O, Hirofumi K, Santhoshi S, Takuya M, Ichiro K 1995 Clinical Implications of metastases to the ovary. *Gynecol. Oncol* 59: 124-128.
4. Seef LB, Hoofnagle J H (2006) Epidemiology of hepatocellular carcinoma in areas of low hepatitis B and hepatitis C endemicity. *Oncogene* 25(27): 3771-3777.
5. Jemal A, Siegel R, Ward E, Murray T, Xu, JQ, Thun MJ (2007) Cancer Statistics, *CA Cancer J Clin* 2007: 57:43–66.
6. Brown JL (1999) N-Nitrosamines. *Occup Med* 14: 839–848.
7. Sullivan BP, Meyer TJ, Stershic MT, Keefer LK (1991) Acceleration of N-nitrosation reactions by electrophiles. *IARC Sci Publ* 14:370–374.
8. Reh BD, Fajen JM (1996) Worker exposures to nitrosamines in a rubber vehicle sealing plant. *Am Ind Hyg Assoc J* 57:918–923
9. Kapadia GJ, Azuine MA, Takayasu J, Konoshima T, Takasaki M, Nishino H (2000) *Cancer Lett* 161: 221-229.
10. Atique A, Iqbal M, Ghouse, AKM (1985) Use of *Annona squamosa* and *Piper nigrum* against diabetes. *Fitoterapia* 56 (3): 190-192.
11. Solt D (1976) New principles for the analysis of chemical carcinogenesis. *Nature* 263: 701-703.
12. Gupta RK, Kersari AN, Murthy PS, Chandra R, Tandon V, Watal G (2005) Hypoglycemic and antidiabetic effect of ethanolic extract of leaves of *Annona squamosa* L. in experimental animals. *J ethanopharmacol* 99(1):75-51.
13. Parthasarathy R, Nivethatha M, Brindha P (2007) Hepatoprotective activity of *Caesalpinia bonducella* seeds on paracetamol induced Hepatotoxicity in male albino rats. *Indian Drugs* 44(5): 401-404.
14. Yoshiji H, Nakae D, Kinugasa T, Matsuzaki M, Denda A, Saji T (1991) Inhibitory effect of the iron deficiency on the induction of putative preneoplastic foci rat liver initiated with diethylnitrosamine and promoted by Phenobarbital. *Br J Cancer* 64: 839–842.
15. Lowry OH, Rosebrough NMF, Farr AL, Randall RJ (1951) Protein measurement with the Folin phenol reagent, *J.Biol. Chem*, 193:265, 1951.
16. Jendrassik L, Jrof P (1938). Simplified photometric method for the determination of the blood bilirubin. *Biochem J* 29: 81 – 89.
17. Marklund, S & Marklund, G. (1974). Involvement of superoxide anion radical in the autoxidation of pyrogallol and a convenient assay for superoxide dismutase. *European Journal of Biochemistry*; 47:469-474.

18. Sinha AK (1972) Colorimetric assay of catalase. *Analytical Biochemistry* 47:389- 394.
19. Rotruck JT, Pope AL, Ganther HE, Swanson AB, Hafeman DG, Hoekstra WG (1973) Selenium: Biochemical role as a component of glutathione peroxidase purification and assay. *Science* 179: 588-590.
20. Moron, MS, Depierre JW, Mannervik B (1979). Levels of glutathione, glutathione reductase and glutathione-S-transferase activities in rat lung and liver. *Biochim Biophys Acta* 582(1): 67–78
21. Omaye ST, Turnbull JD, Sauberlich HE (1979) Selected Methods for the Determination of Ascorbic Acid in Animal Cells, Tissues, and Fluids, *Methods Enzymol* 62:3-11.
22. Desai ID (1984) Vitamin E analysis methods for animal tissue. *Methods Enzymol* 105: 138-142.
23. King J (1965 a) The hydrolases-acid and alkaline phosphatases, in: D. Van (Ed.), In *Practical Clinical Enzymology*, Nostrand Company Ltd, London, 1965, pp. 191–208.
24. King, J. (1965b) The transferases—alanine and aspartate transaminases, in: D. Van (Ed.), In *Practical Clinical Enzymology*, Nostrand Company Ltd., London, 1965, pp. 191–208, pp. 121–128.
25. Orłowski M, Meister A (1965) Isolation of γ -glutamyl transpeptidase from hog kidney *J Biol. Chem* 240:338– 347.
26. Ohkawa H, Ohishi N, Yagi K (1979) Assay for lipid peroxidation in animal tissues by thiobarbituric acid reaction. *Analytical Biochemistry* 95: 351-358.
27. Belanger C, Sylvestre, Dufour D (1973) Enzyme-linked immunoassay for alpha-fetoprotein by competitive and sandwich procedures. *Clin Chim Acta* 48: pp. 15–18.
28. Tisdale MJ (2002) Cachexia in cancer patients. *Nat Rev Cancer* 2: 862–871.
29. Luximon-Ramma, A, Bahorun, T, Soobrattee, MA, Aruoma, OI (2002) Antioxidant activities of phenolic, proanthocyanidin, and flavonoid components in extracts of *Cassia fistula*, *J. Agric. Food Chem* 50: 5042–5047.
30. Brawn MK, Chiou WJ, Leach KL (1995) Oxidant-induced activation of protein kinase C in UC11MG cells. *Free Rad Res* 22: 23–37.
31. Nishizuka Y (1989) The family of protein kinase C for signal transduction. *JAMA* 262: 1826–1833.
32. Huang YT, Kuo ML, Liu JY, Huang SY, Lin JK (1995). Inhibition of protein kinase C and proto-oncogene expressions in NIH 3T3 cells apigenin. *Eur J Cancer* 32A: 146–151.
33. Exner R, Wessner B, Manhart, N, Roth E (2000). Therapeutic potential of glutathione. *Wien. Klin. Wochenschr* 112: 610–616.
34. Sallie RJ, Tredger M, Willam R (1991) Drugs and the liver, *Biopharm. Drug Dispos* 12 : 251–259.
35. Bansal AK, Trivedi R, Soni GL, Bhatnagar D (2000) Hepatic and renal oxidative stress in acute toxicity of N-nitrosodiethylamine in rats. *Indian J. Exp. Biol* 38: 916–920.
36. Torel J, Cillard J, Cillard P (1986) Antioxidant activity of flavonoids and reactivity with peroxy radical. *Phytochemistry* 25:383–385.
